

Quadriceps tendon autograft for arthroscopic knee ligament reconstruction: use it now, use it often

Andrew J Sheehan,¹ Volker Musahl,¹ Harris S Slone,² John W Xerogeanes,³
Danko Milinkovic,⁴ Christian Fink,⁵ Christian Hoser,⁵ International Quadriceps Tendon
Interest Group

¹Department of Orthopaedic Surgery, University of Pittsburgh, Pittsburgh, Pennsylvania, USA

²Department of Orthopaedic Surgery, Medical University of South Carolina, Charleston, South Carolina, USA

³Emory Clinic, Atlanta, Georgia, USA

⁴Universitätsklinikum Munster, Klinik für Unfall-Hand- und Wiederherstellungschirurgie Munster, Munster, Nordrhein-Westfalen, Germany

⁵Research Unit for Orthopaedic Sports Medicine and Injury Prevention, Private University UMIT, Innsbruck, Austria

Correspondence to

Dr Andrew J Sheehan,
Department of Orthopaedic Surgery, University of Pittsburgh, Pittsburgh PA 15203, USA;
ajsheehan@gmail.com

Accepted 1 April 2018
Published Online First
28 April 2018

ABSTRACT

Traditional bone-patellar tendon-bone and hamstring tendon ACL grafts are not without limitations. A growing body of anatomic, biomechanical and clinical data has demonstrated the utility of quadriceps tendon autograft in arthroscopic knee ligament reconstruction. The quadriceps tendon autograft provides a robust volume of tissue that can be reliably harvested, mitigating the likelihood of variably sized grafts and obviating the necessity of allograft augmentation. Modern, minimally invasive harvest techniques offer the advantages of low rates of donor site morbidity and residual extensor mechanism strength deficits. New data suggest that quadriceps tendon autograft may possess superior biomechanical characteristics when compared with bone-patella tendon-bone (BPTB) autograft. However, there have been very few direct, prospective comparisons between the clinical outcomes associated with quadriceps tendon autograft and other autograft options (eg, hamstring tendon and bone-patellar tendon-bone). Nevertheless, quadriceps tendon autograft should be one of the primary options in any knee surgeon's armamentarium.

INTRODUCTION

Quadriceps tendon (QT) autografts are used far less commonly than hamstring (HS) tendon and bone-patella tendon-bone (BPTB) grafts in ACL reconstruction (ACLR).^{1–3} Historical studies suggested that the QT autograft had inferior biomechanical properties compared with the native ACL and was associated with unacceptably high rates of residual rotatory knee laxity and quadriceps weakness.^{4–6} These results were based largely on the behaviour of a 'substitution' graft harvest technique which involved extensive dissection of a 13 cm segment of extensor mechanism tissue composed of QT, prepatellar retinaculum and patellar tendon tissue.⁷ It was also observed that the graft harvested using the substitution technique was 14%–21% weaker than the native ACL with respect to ultimate load measurements.⁴ ACLR using autograft harvested using the substitution method has been associated with a 20% incidence of postoperative pivot shift. The substitution graft harvest technique is associated with significant quadriceps weakness persists, especially in women.⁶ Thus, historical arguments diminishing the utility of QT autograft in ACLR were largely based on data derived from an obsolete graft harvest technique.

Modern QT autograft harvest techniques reliably yield a robust volume of soft tissue, while mitigating

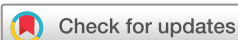the likelihood of donor site morbidity and/or quadriceps strength deficits. Promising clinical data continues to emerge regarding the suitability of QT autograft in both primary and revision knee ligament reconstruction.^{8–9} The purpose of this review is to provide (1) a brief overview of relevant anatomy of the QT tendon and technical considerations for graft harvest; (2) the biomechanical rationale for QT autograft use and (3) an appraisal of the clinical applications and results associated with its use in knee ligament reconstruction.

NEW INFORMATION ON ANATOMY

Rather than a uniformly trilaminar tendon fibre arrangement as traditionally described, the QT is composed of varying tissue configurations, with bilaminar, complex trilaminar and quadrilaminar fibre orientations observed.¹⁰ Despite this variability, a thin fatty layer generally exists between the superficial rectus femoris and deep vastus intermedius; this can be used as a landmark and followed distally to the common QT and the proximal extent of the suprapatellar pouch. Additionally, this layer provides a natural demarcation for splitting the tendon into two limbs suitable for double bundle reconstruction techniques.^{11–12}

The QT is 7–8.5 cm in length from the superior pole of the patella extending proximally to the myotendinous junction of the rectus femoris. This tendon length facilitates the harvest of both a soft tissue only and soft tissue with patella bone block autograft (figures 1A and 2B.) The width of the tendon ranges between 2.5 and 3 cm, with the greatest width found approximately 3 cm proximal to the tendon's insertion on the patella.^{13–15} Additionally, the thickness of the QT is greatest at its distal insertion on the patella, measuring 18±3 mm in males and 16±2 mm in females.¹⁵ The tendon's thickness remains relatively constant throughout the distal 6 cm, measuring 7.4 mm, 7.4 mm and 7.1 mm at 10, 30 and 60 mm proximal to its distal insertion.¹⁵

The variability in QT size between patients may be explained by patient-specific anthropometrics. Ultrasound measurements of skeletally immature patients reveals predictable increases in QT thickness relative to age, height and weight.¹⁶ Moreover, a separate analysis showed height to be the most important predictor of length of the tendinous portion of the QT graft among a cohort of patients, 34.9±12.6 years of age (range: 17–60 years).¹⁵ These relationships can be used preoperatively to verify that the harvested autograft will be



To cite: Sheehan AJ, Musahl V, Slone HS, et al. *Br J Sports Med* 2018;**52**:698–701.

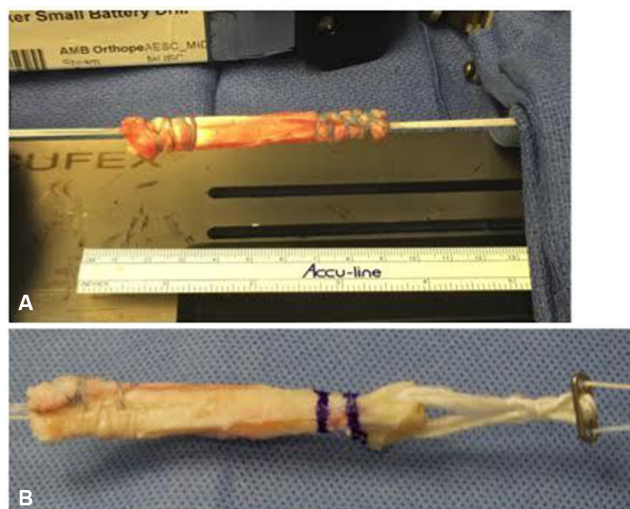

Figure 1 (A) Soft tissue-only quadriceps tendon autograft and (B) quadriceps tendon autograft harvested with a patella bone block.

of sufficient diameter and length to accommodate ligamentous reconstructions.

Overall, the dimensions of the quadriceps facilitate harvesting a robust graft while preserving substantial residual, donor-site tissue. Using volumetric analyses of three-dimensional models of patellar tendon and QT after the removal of a 80 mm long \times 10 mm wide graft, Xerogeanes *et al* showed that the intra-articular volume of the QT graft was 87.5% greater than that of the patellar tendon graft, while harvesting of the QT autograft left a mean percentage volume of residual QT that was greater than that left after patella tendon graft harvest (61.3% v. 56.6%, respectively).¹⁵

The relationship between the QT and the suprapatellar pouch is also relatively consistent. The pouch extends proximally no more than 5 cm from the superior pole of the patella.¹⁷ Consequently, dissection proximal to this level is unlikely to violate the suprapatellar pouch. Beyond the suprapatellar pouch, dissection

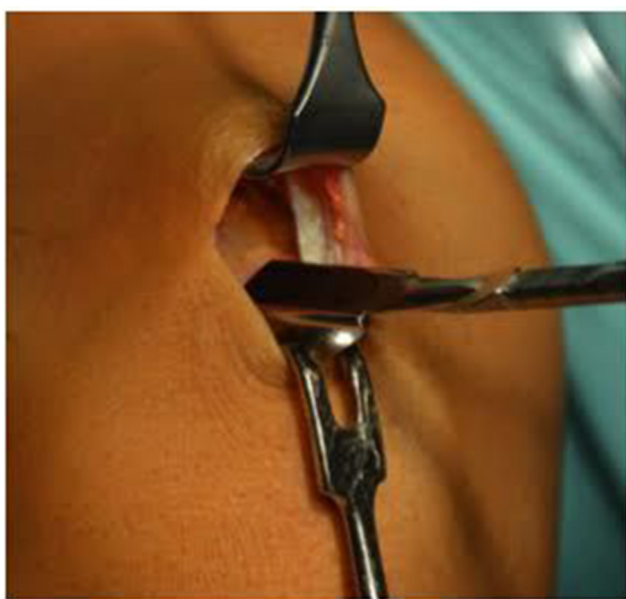


Figure 2 Quadriceps tendon autograft harvested via minimally invasive technique through a 2–3 cm transverse incision centred over the superior pole of the patella.

should not continue proximally into the myotendinous junction (6–8 cm proximal to the patella) to limit cosmetic deformities, postoperative haematoma and, more importantly, functional strength deficits.

The adjacent vascular anatomy should also be considered when planning QT graft harvest. The descending branch of the lateral circumflex femoral artery courses distally between the vastus lateralis and rectus femoris, anastomosing with branches of the lateral superior genicular artery. Therefore, a centrally based graft harvest within the QT that spares the lateral perforating vessels and avoids violation of the quadriceps muscle will mitigate the likelihood of postoperative haematoma.

Recently described techniques for minimally invasive QT autograft harvest both with and without a patellar bone block have exploited a more precise understanding of the native QT anatomy. Using a 2–3 cm transverse incision centred over the superior pole of the patella, Fink *et al* have described a minimally invasive harvest technique using a double knife 8–12 mm in width (Karl Storz, Tuttlingen, Germany) and a series of specialised tendon separator and cutter (Karl Storz) to truncate the autograft proximally¹⁸ (figure 2). Slone *et al* have described a similar minimally invasive soft tissue-only harvest technique using a 1.5–2 cm longitudinal incision extending proximally from the superior pole of the patella, just lateral to its midpoint.¹⁹ The QT is incised from distal to proximal with a triple blade harvest knife (Arthrex, Naples, Florida, USA) using a ‘push’ technique and cut proximally using QT Stripper/Cutter (Arthrex) (figure 3A–C).

BIOMECHANICAL PROPERTIES OF QT AUTOGRAFT

Recent biomechanical data pertaining to the structural properties of QT autograft have demonstrated superior results compared with BPTB autograft with respect to load to failure, strain at failure and Young’s modulus of elasticity. QT autograft has been shown to have a significantly larger cross-sectional area ($91.2 \pm 10 \text{ mm}^2$) than BPTB autograft ($48.4 \pm 8 \text{ mm}^2$) ($p=0.005$)²⁰ and significantly greater ultimate load to failure (QT: $2185.9 \pm 758.8 \text{ N}$ vs BPTB: $1580.6 \pm 479.4 \text{ N}$, $p=0.45$). It should be noted that majority of these data are based on QT autograft harvested with a patellar bone block, and there is comparatively less that has been studied with respect to soft tissue-only QT autografts. The load to tendon failure of a 1 cm wide \times 9 cm long full thickness QT autograft ($1075 \pm 449 \text{ N}$) has been observed to be 1.36 times greater than that of a comparably sized patella tendon graft.¹³ Comparison of the strain behaviours of 1 cm wide QT and patellar tendon before and after cyclic conditioning (200 cycles between 50 and 800 N at 0.5 Hz) demonstrated the strain failure for BPTB grafts to be $14.4\% \pm 3.3\%$ versus $11.2\% \pm 2.2\%$ ($p=0.04$) for QT grafts.¹⁴ Additionally, significantly larger cross-sectional areas for preconditioned QT grafts compared with BPTB grafts of identical width have been observed ($61.9 \pm 9.0 \text{ mm}^2$ vs $34.5 \pm 4.4 \text{ mm}^2$, $p<0.001$).

Apart from the application of QT in ACL reconstruction, QT has also been used in PCL reconstruction (PCLR).^{21–28} However, comparatively less has been written about the biomechanical performance of QT autograft in this setting. A recent cadaveric analysis elucidated the biomechanical properties of the native PCL to QT-PCL reconstructed knees and Achilles tendon with bone block allograft-PCL reconstructed knees.²⁹ Both QT and Achilles tendon with bone block allografts were prepared with an 11 mm wide by 25 mm long bone block and a tendon length of 100 mm. Although neither QT nor Achilles tendon with bone

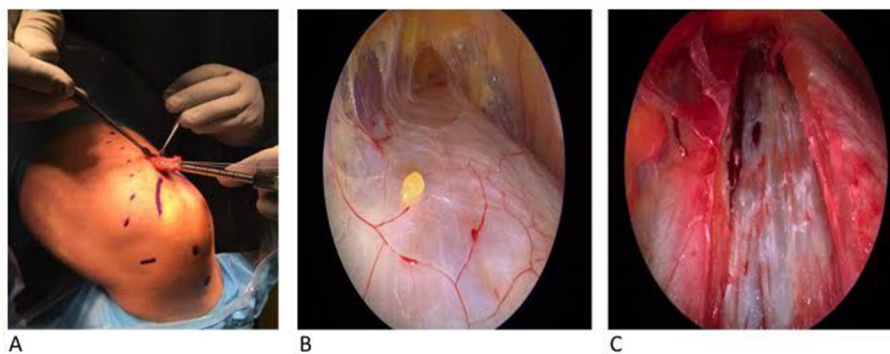


Figure 3 (A) Quadriceps tendon (QT) autograft harvested via minimally invasive technique through a 2 cm longitudinal incision extending proximally from the superior pole of the patella. (B) Inspection of the QT with the 30° arthroscope inserted into the longitudinal incision viewing from distal to proximal. (C) Residual QT postharvest when viewed in a similar fashion.

block allograft demonstrated comparable amounts of creep deformation and ultimate load to that of the intact PCL, QT was associated with greater maximum forces during failure testing (QT: 616.19 ± 148.07 vs Achilles tendon with bone block: 616.19 ± 123.72 , $p=0.048$).

CLINICAL RESULTS

ACL reconstruction

The suitability of QT autograft—with or without patella bone block—in ACL reconstruction has been established in the literature as shown by Slone *et al* in a systematic review of 1756 ACL reconstructions, 1154 of which were performed with QT autograft.⁸ However, it should be noted that these authors did not complete a quality assessment of the studies included in their review. Multiple authors have reported favourable results of ACL reconstruction with QT autograft with respect to postoperative knee stability (arthrometric testing, Lachman testing, pivot-shift testing), range of motion and functional outcomes.^{23 30–37} Moreover, various series have also suggested that QT autograft may be preferable to BPTB autograft in terms of donor site morbidity.^{31–33 35 36 38}

Recently, several comparative studies have assessed for differences in clinical outcomes between ACLR performed with HS autograft and QT autograft. A comparative cohort study comprised 45 patients with QT with patella bone block and 41 patients with HS autograft at a mean follow-up of 3.6 ± 0.4 years showed that the QT autograft group reported significantly better Lysholm, Knee injury and Osteoarthritis Outcome Score (KOOS) Symptoms and KOOS Sport functional scores compared with those of the HS autograft group.³⁹ Additionally, a significantly larger proportion of patients from the QT autograft group had a Lachman grade 0 (93% vs 46%, $p<0.005$) and smaller side-to-side differences in anterior tibial translation as measured with the KT-1000 arthrometer (1.1 ± 0.9 mm vs 3.1 ± 1.3 mm, $p=0.37$.) No significant differences were observed in graft rerupture rates between QT and HS autograft groups. Comparable results among 80 patients undergoing ACLR using partial thickness (5 mm) QT with patella bone block autograft (40 patients) and HS autograft (40 patients) have been reported, with no significant differences between groups at any time point (preinjury, 6 months, 12 months, 24 months postoperative) in Lysholm, pain (as represented by Visual Analogue Scale (VAS)), Tegner Activity Level.⁴⁰

The effect of QT autograft on knee extensor strength has also been a matter of interest in comparisons between ACLR performed with QT and HS autograft, with somewhat heterogeneous results being reported by multiple authors. Retrospectively compared isokinetic data on two groups of 48 patients matched according to

age, sex and body mass index (BMI) showed no significant differences between groups in knee extensor strength at both 60°/s and 180°/s at any time point postoperative. Conversely, the HS autograft group demonstrated significantly diminished knee flexor strength at 2 years postoperative relative to the contralateral lower extremity.¹¹ A similar analysis focused on the differential muscle strength ratio (Hamstring/Quadriceps ratio (H/Q)) observed in the affected lower extremity, as HS weakness in the setting of preserved quadriceps strength may be a risk factor for ACL rupture in females.⁴¹ While significant differences between groups were observed in quadriceps strength, those patients with QT autograft ACLR demonstrated higher H/Q ratios, which the authors hypothesised may be protective against graft rerupture in the first year after surgery.

PCL reconstruction

Because of its excellent biomechanical properties and reliably robust dimensions, the QT is also well suited for PCL reconstruction. Chen *et al* reported on outcomes of single bundle PCL reconstructions using an 8 cm QT autograft with 20×10 mm patella bone block in 32 patients, 29 of which were available for follow-up at 3 years postoperative. Isolated PCL reconstructions were performed in 24 of 29 (83%) of cases. Satisfactory results were observed in terms of functional outcomes at final follow-up (mean Lysholm score: 90.17 ± 9.71) and residual laxity as represented by posterior tibial translation with the KT-1000 (15 of 29 (86%) patients with 5 mm or less.)

COMPLICATIONS

Harvest of the QT can have complications. Multiple donor-site morbidities have been reported, including bleeding and haematoma formation, cosmetic deformities of the distal thigh and patella fracture in cases where a bone block is harvested.^{8 32} Patella fracture, in particular, is a troubling, but exceedingly rare complication of QT autograft harvest, occurring in 4 of 1154 (0.03%) ACLR.⁸ However, this rate is comparable to the fracture rate (0.01%) associated with BTB autograft reported in one large series of 1725 patients.⁴² Nevertheless, should a patellar bone block being harvested with the QT, it is advisable that it should not exceed 30% of the patellar thickness, and it should not be harvested from the lateral aspect of the patella.⁴³ Should the surgeon prefer to negate the risk of patella fracture entirely, the QT can be harvested as a soft tissue-only autograft (figure 1A.)

REHABILITATION

The functional consequences of ACL and PCL injury and reconstruction on the quadriceps and HS musculature are well described but there is a relative paucity of data available pertaining to the optimal rehabilitation tactic specific to ACLR or PCLR performed with QT autograft. There is heterogeneous evidence on the extent of observed amounts of residual quadriceps strength deficits after QT ACLR.^{41–44} The multiple reports outlined above that demonstrated equivalent if not superior functional outcomes of QT ACLR compared with either BPTB or HS ACL mean that postoperative rehabilitation strategies need not necessarily be altered significantly to achieve acceptable clinical results. Moreover, the preservation of knee flexion strength afforded by QT autograft harvest may be advantageous in maintaining a more appropriate dynamic balance between quadriceps and HS strength.^{41–45}

As is typical of postoperative ACLR rehabilitation regimens, focus should be placed on restoring quadriceps strength, including using open-chain exercises in the protected range from 90° to 60° of knee flexion that limit anterior tibial translation while still allowing isolation of the quadriceps.⁴⁶ In the event of harvest site morbidity in the rehabilitation period, an approach similar to that taken for quadriceps tendinopathy may be used. This involved preferential stretching of the rectus femoris and systematic loading of the quadriceps to increase tolerance to load. A criterion-based approach to ACLR rehabilitation is recommended, with progression to the subsequent stage of rehabilitation occurring only after objectively measured indices of physical performance have been met.^{47–48} Similarly, recommendations for rehabilitation following PCLR with QT autograft do not vary substantially from generally accepted regimens—posterior tibial translation should be prevented with knee flexion for the first 6 weeks after surgery with resisted HS strengthening beginning 12 weeks from surgery. The use of a dynamic force (DF) brace (Rebound PCL brace, Össur, Foothill Ranch, California, USA) may be of particular utility in this setting as well in order to protect the ligamentous reconstruction. Applying an anteriorly directed force to the posterior aspect of the proximal tibia that increases with knee flexion, the DF brace has been shown to more closely replicate the in situ loading profile of the native PCL when compared with analogous, static force braces.⁴⁹

What is already known

- ▶ The quadriceps tendon has been previously described as a viable source of autograft tissue for anterior cruciate reconstruction
- ▶ Minimally invasive harvest techniques mitigate the likelihood of harvest site morbidity

What are the new findings?

- ▶ Modern techniques of quadriceps tendon autograft yield a volume and length of tissue that is comparable to bone-patellar tendon-bone autografts.
- ▶ Recent biomechanical investigations have indicated that quadriceps tendon autograft is superior to bone-patellar tendon-bone autograft in terms of load to failure, strain at failure, and Young's modulus of elasticity
- ▶ Clinical data suggests that quadriceps tendon is a suitable autograft option for both anterior cruciate ligament and posterior cruciate ligament reconstructions.

CONCLUSION

The renaissance of the use of QT autograft in knee ligament reconstruction has been borne out of advances in contemporary understandings of the relevant anatomy, improved harvest techniques, predictable graft size, versatility in the skeletally immature, less donor site morbidity, and an emerging body of clinical evidence that suggests outcomes to be equivalent, if not superior to other autograft options.

Collaborators International Quadriceps Tendon Interest Group: Andrew J Sheehan, Volker Musahl, Harris Slone, John Xerogeanes, Danko Milinkovic, Christian Hoser, Christian Fink, Jon Karlsson, Lars Engebretsen, Marie Askenberger, Karl Peter Benedetto, Myun Chun Lee, Peter Fauno, Freddie H Fu, James J Irrgang, Andrew Lynch, John P Fulkerson, Hege Grindem, Mirco Herbot, Juergen Hoehner, Martin Lind, Wolf Petersen, Robert Steensen, Jacob Strauss.

Contributors AJS, VM, DM and HSS contributed directly to the writing of the manuscript. CH, JWX and CF offered critical reviews of the manuscript and participated in the editing process.

Funding The authors have not declared a specific grant for this research from any funding agency in the public, commercial or not-for-profit sectors.

Competing interests LE is a member of the International Quadriceps Tendon Interest Group, and he was not part of the peer review process. The authors report the following conflicts of interest or sources of funding: JWX reports grants, personal fees and non-financial support from Arthrex during the conduct of the study; grants from Arthrex, outside the submitted work. The remaining authors have no disclosures relevant to the publication of this review.

Patient consent Not required.

Provenance and peer review Not commissioned; externally peer reviewed.

© Article author(s) (or their employer(s) unless otherwise stated in the text of the article) 2018. All rights reserved. No commercial use is permitted unless otherwise expressly granted.

REFERENCES

- 1 Middleton KK, Hamilton T, Irrgang JJ, *et al*. Anatomic anterior cruciate ligament (ACL) reconstruction: a global perspective. Part 1. *Knee Surg Sports Traumatol Arthrosc* 2014;22:1467–82.
- 2 van Eck CF, Illingworth KD, Fu FH. Quadriceps tendon: the forgotten graft. *Arthroscopy* 2010;26:441–2.
- 3 van Eck CF, Schreiber VM, Mejia HA, *et al*. "Anatomic" anterior cruciate ligament reconstruction: a systematic review of surgical techniques and reporting of surgical data. *Arthroscopy* 2010;26:S2–S12.
- 4 Noyes FR, Butler DL, Grood ES, *et al*. Biomechanical analysis of human ligament grafts used in knee-ligament repairs and reconstructions. *J Bone Joint Surg Am* 1984;66:344–52.
- 5 Stanish WD, Kirkpatrick J, Rubinchikov RM. Reconstruction of the anterior cruciate ligament with a quadriceps patellar tendon graft. Preliminary results. *Can J Appl Sport Sci* 1984;9:21–4.
- 6 Yasuda K, Ohkoshi Y, Tanabe Y, *et al*. Quantitative evaluation of knee instability and muscle strength after anterior cruciate ligament reconstruction using patellar and quadriceps tendon. *Am J Sports Med* 1992;20:471–5.
- 7 Marshall JL, Warren RF, Wickiewicz TL, *et al*. The anterior cruciate ligament: a technique of repair and reconstruction. *Clin Orthop Relat Res* 1979;143:97–106.
- 8 Slone HS, Romine SE, Premkumar A, *et al*. Quadriceps tendon autograft for anterior cruciate ligament reconstruction: a comprehensive review of current literature and systematic review of clinical results. *Arthroscopy* 2015;31:541–54.
- 9 Häner M, Bierke S, Petersen W. Anterior cruciate ligament revision surgery: ipsilateral quadriceps versus contralateral semitendinosus–Gracilis autografts. *Arthroscopy* 2016;32:2308–17.
- 10 Waligora AC, Johanson NA, Hirsch BE. Clinical anatomy of the quadriceps femoris and extensor apparatus of the knee. *Clin Orthop Relat Res* 2009;467:3297–306.
- 11 Lee JK, Lee S, Lee MC. Outcomes of anatomic anterior cruciate ligament reconstruction: bone-quadriceps tendon graft versus double-bundle hamstring tendon graft. *Am J Sports Med* 2016;44:2323–9.
- 12 Caterev S, Nistor DV, Todor A. Anatomic double-bundle anterior cruciate ligament reconstruction with a free quadriceps tendon autograft. *Arthrosc Tech* 2016;5:e1063–e1067.
- 13 Harris NL, Smith DA, Lamoreaux L, *et al*. Central quadriceps tendon for anterior cruciate ligament reconstruction. Part I: Morphometric and biomechanical evaluation. *Am J Sports Med* 1997;25:23–8.
- 14 Stäubli HU, Schatzmann L, Brunner P, *et al*. Mechanical tensile properties of the quadriceps tendon and patellar ligament in young adults. *Am J Sports Med* 1999;27:27–34.

- 15 Xerogeanes JW, Mitchell PM, Karasev PA, *et al.* Anatomic and morphological evaluation of the quadriceps tendon using 3-dimensional magnetic resonance imaging reconstruction: applications for anterior cruciate ligament autograft choice and procurement. *Am J Sports Med* 2013;41:2392–9.
- 16 Todd DC, Ghasem AD, Xerogeanes JW. Height, weight, and age predict quadriceps tendon length and thickness in skeletally immature patients. *Am J Sports Med* 2015;43:945–52.
- 17 Staubli HU. The quadriceps tendon–patellar bone construct for ACL reconstruction. *Sports Med Arthrosc Rev* 1997;5:59–67.
- 18 Fink C, Herbolt M, Abermann E, *et al.* Minimally invasive harvest of a quadriceps tendon graft with or without a bone block. *Arthrosc Tech* 2014;3:e509–e513.
- 19 Slone HS, Ashford WB, Xerogeanes JW. Minimally invasive quadriceps tendon harvest and graft preparation for all-inside anterior cruciate ligament reconstruction. *Arthrosc Tech* 2016;5:e1049–e1056.
- 20 Shani RH, Umpierrez E, Nasert M, *et al.* Biomechanical comparison of quadriceps and patellar tendon grafts in anterior cruciate ligament reconstruction. *Arthroscopy* 2016;32:71–5.
- 21 Aglietti P, Giron F, Buzzi R, *et al.* Anterior cruciate ligament reconstruction: bone–patellar tendon–bone compared with double semitendinosus and gracilis tendon grafts. A prospective, randomized clinical trial. *J Bone Joint Surg Am* 2004;86-A:2143–55.
- 22 Chen CH, Chen WJ, Shih CH, *et al.* Arthroscopic posterior cruciate ligament reconstruction with quadriceps tendon autograft: minimal 3 years follow-up. *Am J Sports Med* 2004;32:361–8.
- 23 Chen CH, Chuang TY, Wang KC, *et al.* Arthroscopic anterior cruciate ligament reconstruction with quadriceps tendon autograft: clinical outcome in 4–7 years. *Knee Surg Sports Traumatol Arthrosc* 2006;14:1077–85.
- 24 Yp L, Hsu KY, Chen LH, *et al.* Simultaneous arthroscopic reconstruction of the anterior and posterior cruciate ligament using hamstring and quadriceps tendon autografts. *J Trauma* 2009;66:780–8.
- 25 Wu CH, Chen AC, Yuan LJ, *et al.* Arthroscopic reconstruction of the posterior cruciate ligament by using a quadriceps tendon autograft: a minimum 5-year follow-up. *Arthroscopy* 2007;23:420–7.
- 26 Richards RS, Moorman CT. Use of autograft quadriceps tendon for double-bundle posterior cruciate ligament reconstruction. *Arthroscopy* 2003;19:906–15.
- 27 Noyes FR, Barber-Westin SD. Posterior cruciate ligament revision reconstruction, part 2: results of revision using a 2-strand quadriceps tendon–patellar bone autograft. *Am J Sports Med* 2005;33:655–65.
- 28 Noyes FR, Barber-Westin SD. Two-strand posterior cruciate ligament reconstruction with a quadriceps tendon–patellar bone autograft: technical considerations and clinical results. *Instr Course Lect* 2006;55:509–28.
- 29 Forsythe B, Haro MS, Bogunovic L, *et al.* Biomechanical evaluation of posterior cruciate ligament reconstruction with quadriceps versus achilles tendon bone block allograft. *Orthop J Sports Med* 2016;4:232596711666006.
- 30 Kim SJ, Lee SK, Choi CH, *et al.* Graft selection in anterior cruciate ligament reconstruction for smoking patients. *Am J Sports Med* 2014;42:166–72.
- 31 Kim SJ, Kumar P, Oh KS. Anterior cruciate ligament reconstruction: autogenous quadriceps tendon–bone compared with bone–patellar tendon–bone grafts at 2-year follow-up. *Arthroscopy* 2009;25:137–44.
- 32 Gorschewsky O, Klakow A, Pütz A, *et al.* Clinical comparison of the autologous quadriceps tendon (BQT) and the autologous patella tendon (BPTB) for the reconstruction of the anterior cruciate ligament. *Knee Surg Sports Traumatol Arthrosc* 2007;15:1284–92.
- 33 Han HS, Seong SC, Lee S, *et al.* Anterior cruciate ligament reconstruction: quadriceps versus patellar autograft. *Clin Orthop Relat Res* 2008;466:198–204.
- 34 Gorschewsky O, Stapf R, Geiser L, *et al.* Clinical comparison of fixation methods for patellar bone quadriceps tendon autografts in anterior cruciate ligament reconstruction: absorbable cross-pins versus absorbable screws. *Am J Sports Med* 2007;35:2118–25.
- 35 Kim SJ, Chang JH, Kim TW, *et al.* Anterior cruciate ligament reconstruction with use of a single or double-bundle technique in patients with generalized ligamentous laxity. *J Bone Joint Surg Am* 2009;91:257–62.
- 36 Lund B, Nielsen T, Faunø P, *et al.* Is quadriceps tendon a better graft choice than patellar tendon? a prospective randomized study. *Arthroscopy* 2014;30:593–8.
- 37 Akoto R, Hoehner J. Anterior cruciate ligament (ACL) reconstruction with quadriceps tendon autograft and press-fit fixation using an anteromedial portal technique. *BMC Musculoskelet Disord* 2012;13:161.
- 38 Geib TM, Shelton WR, Phelps RA, *et al.* Anterior cruciate ligament reconstruction using quadriceps tendon autograft: intermediate-term outcome. *Arthroscopy* 2009;25:1408–14.
- 39 Cavaignac E, Coulin B, Tscholl P, *et al.* Is quadriceps tendon autograft a better choice than hamstring autograft for anterior cruciate ligament reconstruction? A comparative study with a mean follow-up of 3.6 years. *Am J Sports Med* 2017;45:1326–32.
- 40 Runer A, Wierer G, Herbst E, *et al.* There is no difference between quadriceps- and hamstring tendon autografts in primary anterior cruciate ligament reconstruction: a 2-year patient-reported outcome study. *Knee Surg Sports Traumatol Arthrosc* 2018;26.
- 41 Fischer F, Fink C, Herbst E, *et al.* Higher hamstring-to-quadriceps isokinetic strength ratio during the first post-operative months in patients with quadriceps tendon compared to hamstring tendon graft following ACL reconstruction. *Knee Surg Sports Traumatol Arthrosc* 2018;26.
- 42 Lee GH, McCulloch P, Cole BJ, *et al.* The incidence of acute patellar tendon harvest complications for anterior cruciate ligament reconstruction. *Arthroscopy* 2008;24:162–6.
- 43 Ferrer GA, Miller RM, Murawski CD, *et al.* Quantitative analysis of the patella following the harvest of a quadriceps tendon autograft with a bone block. *Knee Surg Sports Traumatol Arthrosc* 2016;24:2899–905.
- 44 Iriuchishima T, Ryu K, Okano T, *et al.* The evaluation of muscle recovery after anatomical single-bundle ACL reconstruction using a quadriceps autograft. *Knee Surg Sports Traumatol Arthrosc* 2017;25:1449–53.
- 45 Hughes JD BJ, Hirsch A, Musahl V, *et al.* Comparison of short-term biodex results after anatomic ACL reconstruction between three autografts. New Orleans, Louisiana: AAOS 2018 Annual Meeting, 2018.
- 46 Escamilla RF, Macleod TD, Wilk KE, *et al.* Anterior cruciate ligament strain and tensile forces for weight-bearing and non-weight-bearing exercises: a guide to exercise selection. *J Orthop Sports Phys Ther* 2012;42:208–20.
- 47 Lynch AD, Cummer K, Joreitz R, *et al.* Criterion-based approach for rehabilitation after ACL reconstruction. In: Nakamura N, Zaffagnini S, Marx RG, eds. *Controversies in the technical aspects of ACL reconstruction: an evidence-based medicine approach*. Berlin: Heidelberg: Springer Berlin Heidelberg, 2017:513–25.
- 48 Lynch AD, Chmielewski T, Bailey L, *et al.* Current concepts and controversies in rehabilitation after surgery for multiple ligament knee injury. *Curr Rev Musculoskelet Med* 2017;10:328–45.
- 49 LaPrade RF, Smith SD, Wilson KJ, *et al.* Quantification of functional brace forces for posterior cruciate ligament injuries on the knee joint: an in vivo investigation. *Knee Surgery, Sports Traumatology, Arthroscopy* 2015;23:3070–6.